The Physician and Sportsmedicine

ISSN: 0091-3847 (Print) 2326-3660 (Online) Journal homepage: https://www.tandfonline.com/loi/ipsm20

Everything pectoralis major: from repair to transfer

Kamali Thompson, Young Kwon, Evan Flatow, Laith Jazrawi, Eric Strauss & Michael Alaia

To cite this article: Kamali Thompson, Young Kwon, Evan Flatow, Laith Jazrawi, Eric Strauss & Michael Alaia (2020) Everything pectoralis major: from repair to transfer, The Physician and Sportsmedicine, 48:1, 33-45, DOI: 10.1080/00913847.2019.1637301

To link to this article: https://doi.org/10.1080/00913847.2019.1637301

Accepted author version posted online: 27 Jun 2019.
Published online: 23 Jul 2019.

Submit your article to this journal

Article views: 120

View related articles

View Crossmark data

Full Terms & Conditions of access and use can be found at
https://www.tandfonline.com/action/journalInformation?journalCode=ipsm20

THE PHYSICIAN AND SPORTSMEDICINE
2020, VOL. 48, NO. 1, 33–45
https://doi.org/10.1080/00913847.2019.1637301

Taylor & Francis
Taylor & Francis Group

REVIEW

Everything pectoralis major: from repair to transfer

Kamali Thompson[a], Young Kwon[a], Evan Flatow[b], Laith Jazrawi[a], Eric Strauss[a] and Michael Alaia[a]

[a]Division of Sports Medicine, Department of Orthopaedic Surgery, NYU Langone Health, New York, NY; [b]Department of Orthopaedic Surgery, The Mount Sinai Hospital, New York, NY, USA

ABSTRACT

Background: Pectoralis major ruptures are increasing in incidence primarily due to an increase in awareness, activity level among young males between 20 and 40 years of age, and use of anabolic steroids. Although the majority of pectoralis major ruptures are acute injuries, many chronic ruptures are unrecognized and it is imperative to understand the proper evaluation of these injuries, as well as the appropriate treatment for acute and chronic ruptures.

Purpose: Pectoralis major ruptures can lead to deformity and physical disability if left untreated. This review paper discusses both acute and chronic ruptures as well as indications for nonoperative treatment and operative treatment to give the reader the best understanding of this diagnosis and proper management.

Methods: A systematic review of the literature was performed using a search of electronic databases. Search terms such as *pectoralis major rupture, pectoralis major repair, pectoralis major tendon transfer*, and *pectoralis major nonoperative treatment* were used. Case reports, systematic reviews, prospective and retrospective studies were included to provide a comprehensive review. The only exclusion criteria consisted of studies not published in English. This review article includes the anatomy and biomechanics of the pectoralis major muscle, proper evaluation of the patient, operative and nonoperative treatment of acute and chronic pectoralis major ruptures, and outcomes of the recommended treatment.

Conclusion: Nonoperative treatment is indicated for patients with medical comorbidities, older age, incomplete tears, or irreparable damage. Patients treated non-operatively have been shown to lose strength, but regain full range of motion. Patients with surgery before 6 weeks reported better outcomes than patients with surgery between 6 and 8 weeks. The chronicity of the rupture (>8 weeks) increases the likelihood of reconstruction, involving the use of autografts or allografts. Patients treated with delayed repair had significantly better strength, satisfaction, and outcomes than patients with nonoperative treatment. The pectoralis tendon can also be transferred in patients with rotators cuff tears, atrophy, or significant functional limitation. Tendon transfers have been shown to have unpredictable outcomes, but overall satisfactory results.

ARTICLE HISTORY
Received 25 September 2018
Accepted 13 June 2019

KEYWORDS
Pectoralis major rupture; pectoralis major repair; tendon transfer

Introduction

Pectoralis major ruptures are increasing in incidence, especially within the last several decades [1–8]. This type of injury can lead to cosmetic deformity, as well as physical disability [9]. Although the majority of pectoralis major ruptures are acute injuries, many chronic ruptures are unrecognized and it is imperative to understand the proper evaluation of these injuries, as well as the appropriate treatment for acute and chronic ruptures [10]. Nonoperative treatment is indicated for patients with medical comorbidities, older age, incomplete tears, or irreparable damage [11–13]. Patients treated non-operatively have been shown to lose strength, but regain full range of motion [3,5,8,14–16]. Patients with surgery before 6 weeks have reported better outcomes than patients with surgery between 6 and 8 weeks [2,5,8,15,17–19]. Chronicity of the rupture (>8 weeks) increases the likelihood of reconstruction, involving the use of autografts or allografts [6,20–23]. Patients treated with delayed repair have demonstrated significantly better strength, satisfaction, and outcomes than patients with nonoperative treatment [1,2,8,17,24]. We present a comprehensive review of the evaluation and management of pectoralis major ruptures.

Epidemiology

The majority of acute pectoralis major ruptures occur among young males between 20 and 40 years of age [13,25]. These injuries are fairly uncommon and have the highest incidence in the military and athletic populations [20,26]. According to a 2012 meta-analysis, less than 400 cases had been reported prior to that particular study [4]. Approximately 75% of ruptures are a direct result of sports-related activity (i.e. gymnastics, jujitsu, rugby, American football) with 50% of the

CONTACT Kamali Thompson Kamali.thompson@nyumc.org NYU Langone Health, 333 E 38th St, New York, NY 10039, USA

What is known about the subject: Pectoralis major ruptures are increasing in incidence and have traditionally been treated with nonoperative treatment. Although the majority of pectoralis major ruptures are acute injuries, many chronic ruptures are unrecognized. However, this type of injury can lead to cosmetic deformity, as well as physical disability if left untreated. As a result, surgical techniques are constantly developing to determine the best management for these patients.

What this adds to existing knowledge: This review paper discusses the both acute and chronic ruptures as well as indications for nonoperative treatment and operative treatment, specifically tendon repair versus tendon reconstruction. This paper includes the existing literature as well as expert opinion to give the reader the best understanding of this diagnosis and proper management.

© 2019 Informa UK Limited, trading as Taylor & Francis Group

athletics-related ruptures caused by weightlifting [27]. A recent study by Balzas examining ruptures within the military population determined the incidence to be 60 per 100,000 person years [28]. Unfortunately, the true incidence is unknown as many acute ruptures go unrecognized and evolve into chronic deficiencies [10]. The recent spike in incidence most likely reflects increased awareness, increased activity, and widespread use of anabolic steroids [1,3,19,29].

Anatomy and biomechanics

The pectoralis major is a triangular muscle that lies anterior to the subscapularis and coracobrachialis and inferior to the deltoid [30]. It contains two heads: the superior clavicular head and the inferior sternocostal head. The clavicular head originates at the anterior border of the medial half of the clavicle, from which the fibers run laterally in a downward direction. It is innervated by the lateral pectoral nerve (C5-C7), which exits the lateral cord of the brachial plexus medial to the pectoralis minor, travels with the pectoral branch of thoracoacromial artery, and enters the pectoralis major at a mean of 12.5 cm medial to the humeral insertion (95% confidence interval 10–14.9 cm) [4,30,31]. The primary role of the clavicular head is forward flexion, adduction, and internal rotation of the humerus. The clavicular head is also partially responsible for abduction once the arm is abducted to 90° and adduction with the arm below 90°.

The sternocostal head is the larger of the two muscles, making up 80% of the entire muscle volume and is composed of seven overlapping segments [3,27,32] (Figure 1). The sternocostal head originates from the second to sixth rib and the costal margin of the sternum with the fibers running upward and laterally. The inferior fibers of the pectoralis major are innervated by the medial pectoral nerve (C8-T1), which exits the medial cord of the brachial plexus, travels with the lateral thoracic artery to pierce the pectoralis minor at the midclavicular line and enters the pectoralis major at a mean of 11.0 cm medial to the humeral insertion (95% confidence interval 8.6–15.3 cm) and 2 cm proximal to the inferior edge [4,20,30]. Its' primary role is the forward elevation of the humerus, as well as internal rotation, horizontal adduction, and extension. Tendons from both muscular heads converge laterally and insert on to the lateral lip of the bicipital groove of the humerus and the anterior lip of the deltoid tuberosity [30]. The crossing of the tendons occurs as the inferior sternocostal head rotates 180° transforming it into the posterior lamina, while the clavicular head becomes the anterior lamina [33].

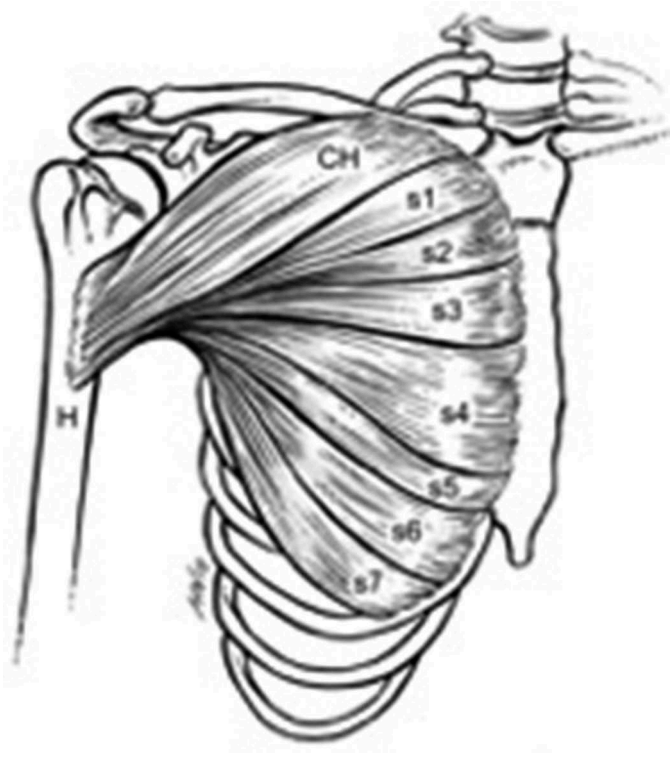

Figure 1. Diagram of the clavicular head and sternocostal heads of the pectoralis major: H = Humerus, CH = Clavicular head, S1-S7 = Sternocostal head (Illustration by Hugh Nachamie).

Acute pectoralis major tears

Mechanism of injury

Acute pectoralis major tears are a result of eccentric lengthening or forced abduction and external rotation of the muscle [19]. Forced abduction and external rotation of the pectoralis major can occur during contact sports (e.g. football, rugby) and combat sports (e.g. boxing, wrestling, fighting). Motions such as the downward portion (or 'negatives') of bench pressing or manual transfers with the shoulder in the extended position in elderly patients can cause excessive contractions and successive rupture [19,34].

The pectoralis major is most vulnerable to rupture with the inferior fibers of the sternal head lengthened at 30° of humeral extension [19]. When the inferior fibers are measured through an arc of 30° of extension they contain an excursion of 40% of the entire muscle, twice the amount of the superior fibers [19]. This increase in excursion causes the inferior fibers to rupture first, followed by the superior sternal head, and finally the clavicular head [19,28].

The most common acute pectoralis major ruptures are tendinous avulsions of the humeral insertion [2] (Table 1). Other frequent locations include intra-muscular, myotendinous, and intratendinous regions [2]. Direct trauma may cause muscle belly injuries and indirect trauma results in tendon avulsions [34]. Complete tears are more common, responsible for approximately 91% of pectoralis major ruptures [2]. However, as partial or incomplete tears may often be missed, the true incidence of incomplete tears is unknown [10].

Evaluation

Acute ruptures are often described as a sudden onset of pain in addition to a palpable or audible pop [32]. Ecchymosis and extensive soft tissue swelling will often be present around the chest wall and upper arm [9,32]. Physical examination shows loss of the axillary fold with a potential area of depression at the deltopectoral groove, amplified with the arm abducted and externally rotated and with forced adduction or with both hands places together anterior to the chest (Figure 2) [3,9,29,32]. Physical examination can also show the 'dropped nipple' sign where the ipsilateral nipple is positioned and

Table 1. Diagram of various locations of pectoralis major ruptures and appropriate treatment (Illustration by Hugh Nachamie).

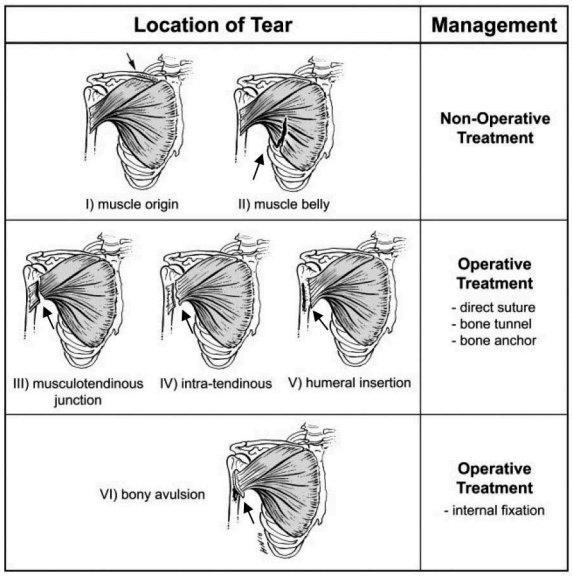

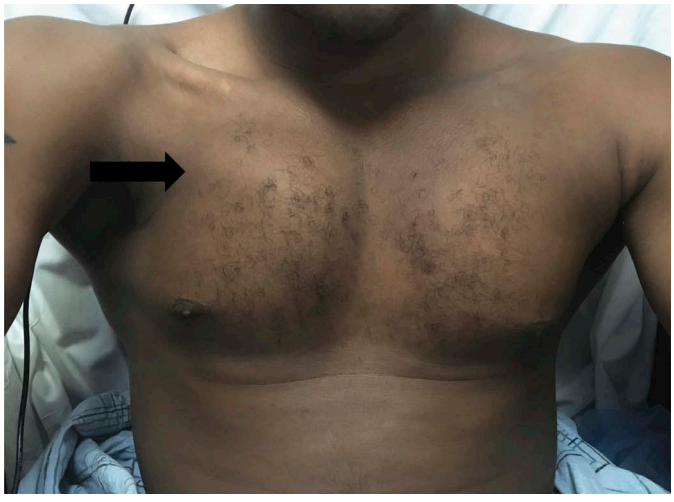

Figure 2. Preoperative photograph showing asymmetric retraction of the right pectoralis major and loss of the typical axillary contour.

points more downward than the contralateral nipple [35]. The examination will also elicit focal tenderness around the upper arm and muscle belly, as well as pain and weakness with adduction and internal rotation [3].

The gold standard for diagnosis of an acute pectoralis major tear is magnetic resonance imaging (MRI) of the chest wall. A standard shoulder MRI is not recommended as it cannot readily identify the injury as the image will not have enough distal inclusion to diagnose the rupture [7]. Axial slices from the quadrilateral space to the deltoid tuberosity provide the most information (Figure 3) [7]. T2-weighted axial images are excellent in the acute setting and T1-weighted more helpful for chronic cases [7,36] (Figure 4). Ultrasound is a common and popular option that may be used for initial screening of the rupture because of its' accessibility and inexpensiveness [9]. Plain radiographs can be used if there is a suspicion of a bone avulsion fragment, a rare occurrence [37].

Classification

The Tietjen classification is the most widely utilized classification system [32]. This system grades pectoralis muscle injury based on the degree of the tear (contusion/partial/complete), location of the tear (muscle origin/muscle belly/musculotendinous junction/insertion) and chronicity (Table 2) [13]. Location and chronicity assess reparability and determine whether operative or nonoperative intervention is the best option [32]. According to the Tietjen classification, Type I injuries are sprains, Type II injuries are partial tears, and Type III complete tears. Complete tears can occur at the muscle origin, muscle belly, myotendinous junction or tendon insertion (allocated III-A, III-B, III-C, III-D, respectively) [13]. Thus far, none of the established classification systems have been tested for reliability or reproducibility. Regardless, the classification of the presenting rupture is advantageous for deciding between nonoperative and operative treatment [28].

Treatment of acute ruptures

Nonoperative treatment

Nonoperative treatment is indicated for patients with certain incomplete tears, irreparable damage (e.g. muscle belly tears), low demand patients accepting of the cosmetic defect or those who are unable or unwilling due to medical comorbidities, age, or the ability to comply with a post-operative rehabilitation protocol [11–13]. Conservative treatment begins with immobilization of the arm with a sling in an adducted and internally rotated position for three weeks with appropriate activity modification [32,38,39]. Active assisted and active motion should begin after 2–4 weeks and resistance strengthening should begin after 8–12 weeks [11,12,39].

Nonoperative treatment outcomes

The outcomes of the pectoralis major repair are graded using the Bak criteria, a classification system defining outcomes as excellent, good, fair, and poor, listed in Table 3 [2]. The most common disadvantage with nonoperative treatment is partial loss of adduction and torque strength [3,5,8,15,16]. Fleury et al. found no difference in isokinetic variables in patients receiving conservative treatment compared to patients undergoing surgery [40]. However, the majority of literature reports a significant decrease in strength resulting in slightly worse outcomes than surgical treatment [3,5,8,15,16] (Table 4). Despite this occurrence, patients typically report excellent or good outcomes [1,3,8]. Only one study, a meta-analysis, showed the majority of patients (80%) reported fair and poor outcomes [2]. Patients also report lower satisfaction with cosmesis than patients who received surgical treatment. Regardless, all patients regained full range of shoulder motion demonstrating nonoperative treatment produces viable results but should be reserved for patients unwilling or unable to have surgery.

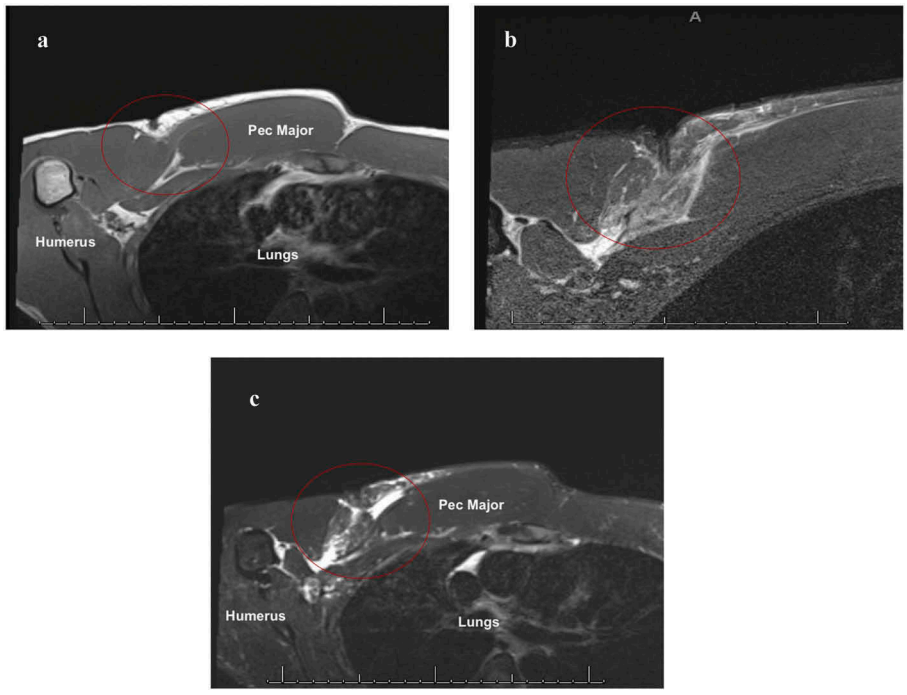

Figure 3. A 34-year-old male with a full thickness tear of the clavicular head off the humerus (a) axial T1-weighted MR image (b, c) Axial T2-weighted fat-suppressed image.

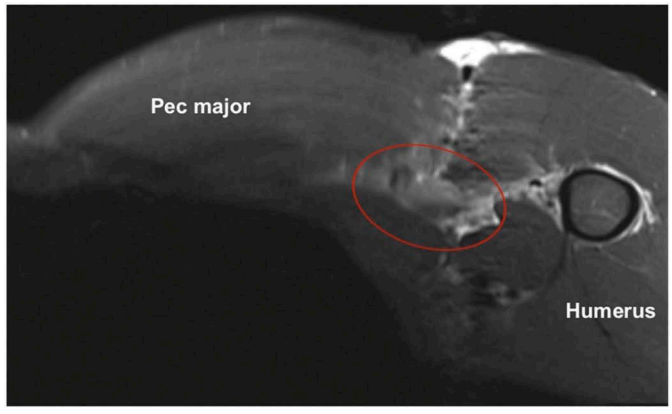

Figure 4. Axial T2-weighted fat-suppressed image of ruptured pectoralis major tendon with significant retraction.

Operative treatment

Operative treatment is recommended for complete tears and certain incomplete tears, such as isolated sternal head ruptures [1–3,5,8,11,13,15,17,19,41,42] (Figure 5). Indications for operative treatment repair also include young patients and high demand patients who plan to return to physical activity [32]. Although the pectoralis major is not required for most daily activities, surgical repair avoids possible complications including loss of strength, aesthetics, and function [2,3,15,19,24,41,42]. While chronicity may affect the surgical technique, it should not be a deterrent from repair [1,4,8,11,12]. Reconstruction or augmentation is rarely necessary unless the tendon appears thin or shredded, but may be considered if the tear is near the musculotendinous junction [42]. However, it is often necessitated in chronic cases secondary to loss of tendon quality and muscle retraction [43].

Table 2. Tietjen classification of pectoralis major rupture based on location and extent[13].

Type	Pectoralis Major Injury Pattern
I	Contusion or muscle train
II	Partial tear
III	Complete tear
III-A	Complete tear of the muscle origin
III-B	Complete tear of the muscle belly
III-C	Complete tear at the musculotendinous junction
III-D	Complete tear at or near the tendinous insertion

Author's preferred treatment

Numerous techniques have been described for pectoralis major repair including the use of bone tunnels, suture anchors, and cortical buttons, as well as different stitch techniques (Mason-Allen, Krakow, etc.) [42,44]. In any case, the cortical bone at the

Table 3. Bak criteria for evaluating pectoralis major repair outcomes[2].

Bak Criteria	
Excellent	Pain free Normal ROM No cosmetic complaints Symmetrical manual adduction strength assessment or less than 10% isokinetic strength loss Return to same level of activity without restrictions
Good	Slight functional impairment with only slight restrictions in movement or strength No cosmetic complaints Slight cosmetic defect Symmetrical manual adduction strength, or less than 20% isokinetic deficit
Fair	Impairment of function Affected return to desired activity Pain or weakness on activity Unsatisfactory cosmetic result
Poor	Permanent inability to return to work Treatment failure after non-surgical treatment Significant complications post operatively Persistent pain or restricted range of motion Significant cosmetic complaints from scarring or an inadequate repair

insertion should be gently decorticated to provide a bony bed for fixation and healing [45]. The authors prefer the cortical button technique because it provides more strength than suture anchors (Figure 6).

During surgical preparation, the patient is placed under general anesthesia and positioned in a modified beach-chair position at 20–45° for improved visualization [45]. The arm can be placed into a pneumatic device or placed onto a padded Mayo stand for improved control of the arm. A marking pen is used to identify important landmarks such as the coracoid process [45]. Surgical exposure can be made at the anterior axillary fold or with a deltopectoral approach [45]. The deltopectoral approach can be made using a 6–8 cm incision over the distal portion of the deltopectoral interval placed slightly medial to better identify the retracted tendon [45]. An incision at axillary fold can be used for a better cosmetic result [30]. After the skin incision, medial and lateral adhesions should be manually lysed in order to gain maximal exposure to the torn tendon.

The fascia overlying the pectoralis is then identified and incised in line with the incision. In the case of complete tears, incision of this fascia can release a large hematoma or seroma and the pectoralis tendon should be easily visualized. However, with isolated sternal tears, it is often necessary to penetrate the fascia over the clavicular head at its inferior margin; allowing for access to the undersurface of the clavicular head, the primary location of the sternal head. If necessary, the muscle-tendon unit can then be mobilized using caution to avoid the medially based pectoral nerves.

Table 4. Conservative Treatment Outcomes.

Reference	Year	Study Type	No. of Patients[a]	Average Post-op Follow up	Nonoperative Treatment Outcomes
Roi et al. [16]	1990	Retrospective case series	3/3	Not specified	Lower isokinetic adduction strength compared to the healthy arm.
Pavlik et al. [15]	1998	Retrospective case series	1/7	6.5 years (0.6–12 yr)	Patient experienced significant weakness of horizontal adduction and internal rotation of arm, surgery was eventually recommended.
Bak et al. [2]	2000	Meta-analysis	24/72	Not specified	43/48 treated surgically for acute ruptures reported excellent/good. 20/24 treated conservatively reported fair/poor.
Schepsis et al. [8]	2000	Retrospective case series	4/17	28 mo. (18 mo-6 yr)	Strength returned to 55% to 85% of preinjury levels, with an average of 67.5%. Satisfaction with cosmesis averaged 56%, with a range of 40% to 70%. Satisfaction with outcomes averaged 51%, with a range of 40% to 70% Peak torque was measured between 63% and 75%.
Hanna et al. [5]	2001	Retrospective case series	12/22	27.2 mo. (1–108 mo.)	Peak torque and work performed returned to 56% of that of the uninjured side
Aarimaa et al. [1]	2004	Meta-analysis	22/73	4.4 yrs (6 mo–10yr)	17/22 (77.3%) reported excellent or good outcomes
de Castro Pochiniet al. [3]	2010	Prospective cohort	10/20	36 mo. (48–72 mo.)	80% reported fair or bad outcomes. 41.2% peak torque deficit, compared to 13.7% deficient in operative group.
Fleury et al. [40]	2011	Prospective cohort	18/33	12 mo.	No difference in isokinetic variables compared to surgical cohort.

[a]No of patients treated conservatively in the study/total number of patients in the study

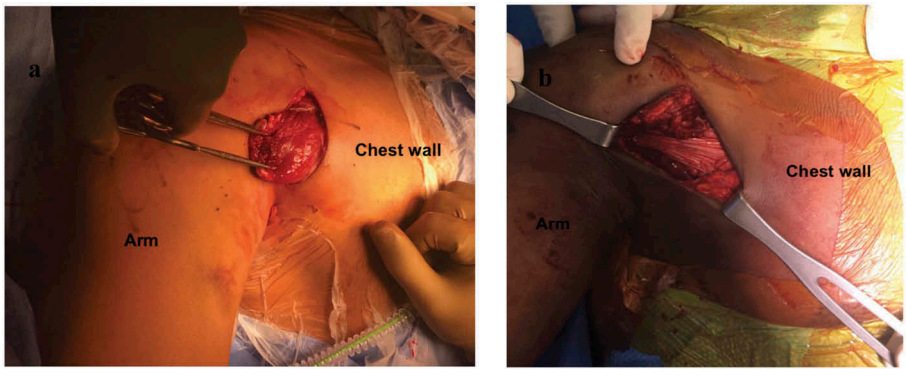

Figure 5. (a) Two clamps delivering the R pectoralis major tendon stump out of the wound (b) Achilles tendon reconstruction for R pectoralis major tear.

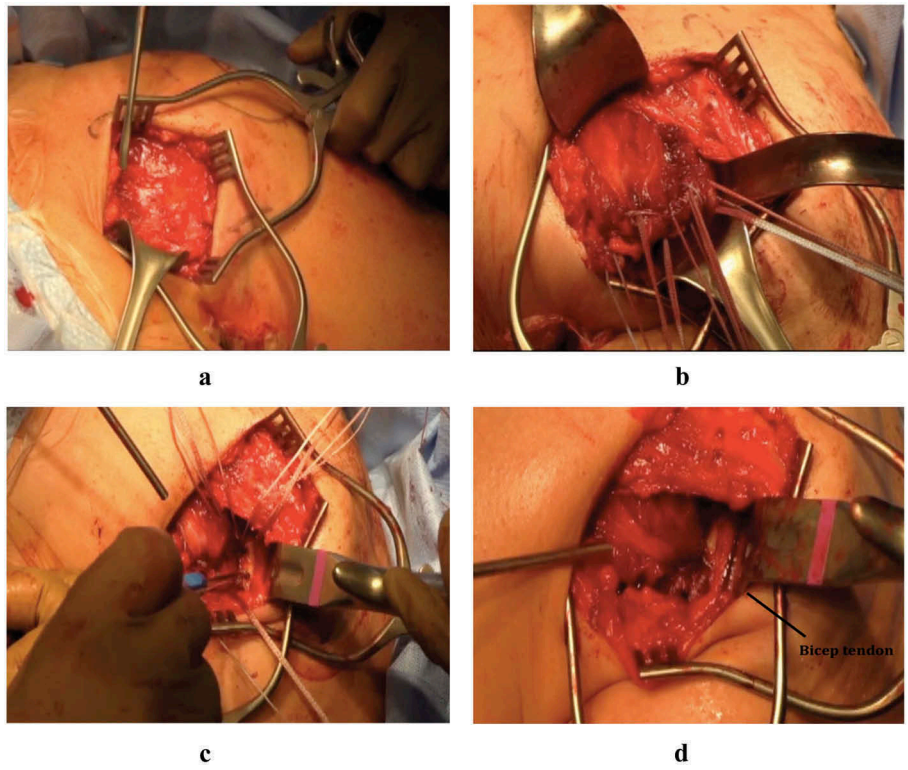

Figure 6. Repair of an Acute Rupture (Left to Right) (a) Tractors are placed exposing the pectoralis major (b) Tape type sutures passed through the tendon (c) Cortical buttons deployed unicortically (d) Tendon attached to humerus/bicep tendon mobility ensured.

In cases where the tear pattern may not be straightforward or is confusing, the deltopectoral interval can be identified by finding the fat stripe and retracting the cephalic vein laterally. This can provide access to the clavicular head which can be traced to its insertion and allow the surgeon to assess the true superior border of the clavicular head and the pectoralis. Regardless of the surgical technique, the long head of the biceps tendon should be identified and retracted to avoid encroachment [45].

The cortical button fixation method begins with whip-stitching the affected myotendinous unit with multiple high tensile strength tape suture (FiberTape, Arthrex Inc., Naples, FL USA) in a Krackow-type fashion. Three to four unicortical drill holes are then placed about 1 cm apart from superior to inferior in a slightly staggered fashion. The leading strands of both sutures are passed through separate titanium cortical buttons and only one limb of each suture is sutured along the tendon [45]. T.he remaining limbs of each suture are passed through the button and tied to secure the button and are twisted 180° to recreate the natural rotation of the pectoralis major tendon and bring the inferior sternal head to a position deep to the clavicular head [45]. The cortical buttons are docked, the high strength suture is tied, followed by the tying of the tape sutures [45]. Although the cortical button technique has shown decreased risk of injury to neurovascular structures, currently there has been no scientific evidence support the use of a specific method of fixation [32].

Postoperative rehabilitation

Postoperative rehabilitation is dependent on the classification of pectoralis major rupture. Muscle-tendon repairs generally require a more stringent rehabilitation period because of potential difficulty obtaining firm anchorage for suturing during the procedure [39]. Some experts suggest conservative treatment for muscle-tendon repairs due to potential surgical obstacles [39]. Since the soft muscle tissue is fragile following the repair, tendon-tendon and muscle-tendon repairs require more time for adequate soft tissue healing. Patients with tendon-tendon repairs are recommended to remain immobilized in a sling for 4 weeks and bone-tendon repairs remain immobilized for 3 weeks [39].

When the patient begins rehabilitation they initially experience limitations with motion due to repair integrity and tendon excursion. Patients should begin passive range of motion (PROM) at 2 weeks, beginning at neutral external rotation and increasing 5 degrees each week [39]. Forward flexion should be passively taken to 45 degrees and increased by 5–10 degrees each week [39]. Abduction should be passively taken to 30 degrees and increased by 5 degree intervals each week. Early in the postoperative phase, active range of motion (AROM) of the shoulder is not allowed, however, AROM of the elbow, forearm, wrist, and hand is encouraged [39]. Patients with bone-tendon repairs should reach full AROM/PROM at 12–14 weeks, while tendon-tendon repairs should reach full AROM/PROM by 14–16 weeks [39]. Patients should not lift more than 50% of 1 maximum repetition until 6 months after their operation [39]. However, patients have been shown to return to the preinjury level before 6 months in several studies with some patients returning to play as early as 2 months [16–18]. Patient counseling is necessary for both operative and conservative treatment as patients with operative treatment may still have residual deformity and/or decrease in strength.

Outcomes of acute ruptures

The current literature on acute repairs represents a heterogeneous population of tears in terms of chronicity and location [2,5,8,14,15,17–19]. Using the Bak criteria, the available case series found 63% to 100% of patients with acute repairs reporting excellent or good outcomes [1,2,8,15,19]. Among the studies listed in Table 5, the definition of acute varied between 2 and 8 weeks. All studies where acute surgery was defined less than 6 weeks showed 90% of patients or greater had excellent or good outcomes [5,8,15]. Patients with surgery between 6 and 8 weeks post injury showed alower percentage, 63–90%, of excellent or good outcomes [2,14,17–19]. Peak torque and work performed returned to 74–113.2%, strength returned to 85–100% of apreinjury level, and 70% or more were able to return to preinjury physical activity level (Table 5).

With any procedure, complications are a concern. Potential complications of surgical management include postoperative infection, tendon re-rupture, postoperative hematoma, heterotopic ossification, and although rare, proximal humerus fractures [15,24,46–49]. While uncommon, the medial and lateral pectoral nerves are also at risk of being damaged because of their exposure during the surgical procedure [29,47]. Thus far, 10 studies have reported complications demonstrating 18% of patients (75/423) have had postoperative complications and 7% of patients (30/423) required a reoperation [7,18,19,29,50–54]. The most common complications included reruptures in 4% of patients (18/423), 61% requiring revision surgery, and wound infection in 4% (17/423), 76% requiring irrigation and debridement [55].

Chronic pectoralis major ruptures

Chronic pectoralis major ruptures have increased in incidence during the last decade (2000–2010) due to an increased interest in health, fitness, and weight training, and use of anabolic steroids [1,3,19,29]. The timeline of chronicity varies between case series ranging from 3 weeks to 8 weeks post injury because it is believed muscle belly retraction may be seen as early as 3 weeks [32]. Chronic injuries can be associated with tendon involution, muscle–tendon retraction/scarring, muscle belly atrophy, and shoulder deconditioning and imbalance [1,3,19,29]. Delay in the diagnosis of pectoralis major ruptures greatly impacts management as chronic ruptures may not be amenable to direct repair thus requiring reconstruction [6,21,56,57].

Table 5. Outcomes of Acute Surgical Repair (<8 weeks).

Reference	Year	Study Type	No. of Surgical Patients	Average Post-op Follow up		Surgical Outcomes
Wolfe et al. [19][a]	1992	Retrospective case series	7	21.5 mo.	6/7 (85.7%) satisfaction	6/7 regained full range of motion. Unilateral tears (4)- torque and work performed were 105.8% and 109.0% of those of the normal arm. Bilateral tears (2) – peak torque and work performed were 109.2% and 113.2% the contralateral side.
Pavlik et al. [15][b]	1998	Retrospective case series	7	6.5 years (0.6–12 yr)	7/7 (100%) excellent	1 patient reported as good had a 20% decrease in horizontal adduction and internal rotation. 6/7 returned to preoperative sports activity.
Bak et al. [2]	2000	Meta-analysis	45	Not specified	40/45 (88.9%) excellent/ good	No poor outcomes
Schepsis et al. [8]	2000	Retrospective case series	6	28 mo. (18 mo-6 yr)	90% to 100% satisfaction	Strength returned to 85% to 100% of preinjury levels, with an average of 94%. Average level of pain relief was 95%, with a range of 85% to 100%. 100% regained full motion Peak torques between 74% and 110%
Hanna et al. [5]	2001	Retrospective case series	9	15 mo. (2–50 mo.)	9/9 (100%) excellent/ good	Peak torque returned to 99% of that of the uninjured side and work performed returned to 97%.
Aarimaa et al. [1]	2004	Meta-analysis	32	4.4 yrs (6 mo–10yr)	30/32 (93.8%) excellent/ good	Use of anabolic steroids associated with better outcome
Kakwani et al. [29]	2007	Retrospective case series	13	23.6 mo. (14–34 mo)	12/13 (92.3%) excellent/ good	11/13 patients were able to return to their pre-injury level of sports
Antosh et al. [17]	2009	Retrospective case series	8		7/8 (87.5%) excellent/ good	100% satisfaction. Lower scores in sports modules, DASH, and work module indicating less disability than the delayed cohort. 7/8 returned to work before 6 months.
He et al. [14]	2010	Retrospective case series	9	6.7 yr	8/9 (89%) excellent/ good	8/9 returned to sports at preinjury levels
de Castro Pochini et al. [3]	2010	Prospective cohort	19	36 mo. (48–72 mo.)	9/10 (90%) excellent/ good	7/10 (excellent) returned to preinjury competitive level. 1/10 (good) returned with reduced performance. 1/10 could not return to competitive level.
Cordasco et al. [18]	2017		40	2.5 yr (6 mo–7 yr)	25/40 (63%) excellent/ good	All patients returned to preinjury activity between 4.5–6.5 months. 23% of patient reported mild difficulty with sports. 3% reported moderate difficulty.

[a]Acute repair defined as <6 weeks
[b]The number of weeks was not defined for an acute repair

Evaluation

The evaluation of a patient is important to determine time from injury, prodromal symptoms, mechanism of injury and risk factors including anabolic steroids [1,41]. The use of anabolic steroids results in stiffer tendons that absorb less energy and fail with less elongation and inferior stress values [32,58,59]. Several findings can be seen on physical examination including medialization of the muscle belly, 'S' sign, 'triangle' sign (maintained clavicular head), exaggeration/hypertrophy of the clavicular head, and a thinner axillary fold [20]. The tendon gap will be palpable or a gap within the muscle belly [20]. Physical exam should help conclude the location, degree of retraction, the potential for mobilization and choice of direct repair versus reconstruction.

Nonoperative treatment

If diagnosis is delayed, the option of nonoperative management is reserved for partial tears, functional sternocostal head, intramuscular tears, low demand patients, elderly, and medical comorbidities [11,12,32,42]. Conservative treatment includes physical therapy specifically for the deltoid and trapezius to increase range of motion as well as activity modification [10].

Reconstruction for chronic tear

Chronic pectoralis major ruptures may be treated with direct repair or reconstruction, depending on the degree and location of tear [8,19,21,42]. Reconstruction is reserved for a complete disruption of the entire insertion site, significant muscle belly or tendon retraction, or distorted tissue quality [60,61] (Figure 7). Tendon graft options for reconstruction include: hamstring autograft, achilles allograft, dermal allograft patch, and fascia lata allograft [6,20–23]. Fixation techniques for stabilizing the graft include transosseous sutures, suture anchors, screws and washers, unicortical buttons, and bone troughs [1,6,8,62]. Due to the limited number of studies available it has yet to be determined which method is the best for reconstruction.

Allografts are popular for reconstruction because they avoid donor site morbidity and demonstrate impressive loading characteristics[60]. Disadvantages to allografts include risk of disease transmission, delayed graft incorporation, and increased risk of rerupture [62,63]. The fascia lata and achilles allografts are the most widely used [22,47,64]. The achilles allograft is a simple technique, amenable to any fixation technique, provides large graft surface area and length, and its' flat, thin shape easily mimics pectoralis major anatomy [60,64]. The fascia lata allograft provides good tension reinforcement, adequate muscle length, patient satisfaction for cosmetic results, and no functional deficits at a 5-year follow up [22]. While the dermal allograft is mainly utilized for rotator cuff repair it has been recommended for pectoralis major reconstruction and has shown to have good outcomes [62]. The acellularity of the dermal allograft reduces graft immunogenicity and increases biocompatibility [60]. Its' thin shape also allows easy mimicry of the pectoralis major muscle, thus reducing graft preparation time [62].

Hamstring and bone patellar tendons have been utilized as autografts for reconstruction, with the hamstring as the more prevalent option [62]. The advantages to using autografts include complete biocompatibility, removal of the risk of disease transmission, the ability to be tailored to mimic pectoralis major anatomy and fill a significant gap [62]. Disadvantages of autografts include potential proximal nerve injury and donor

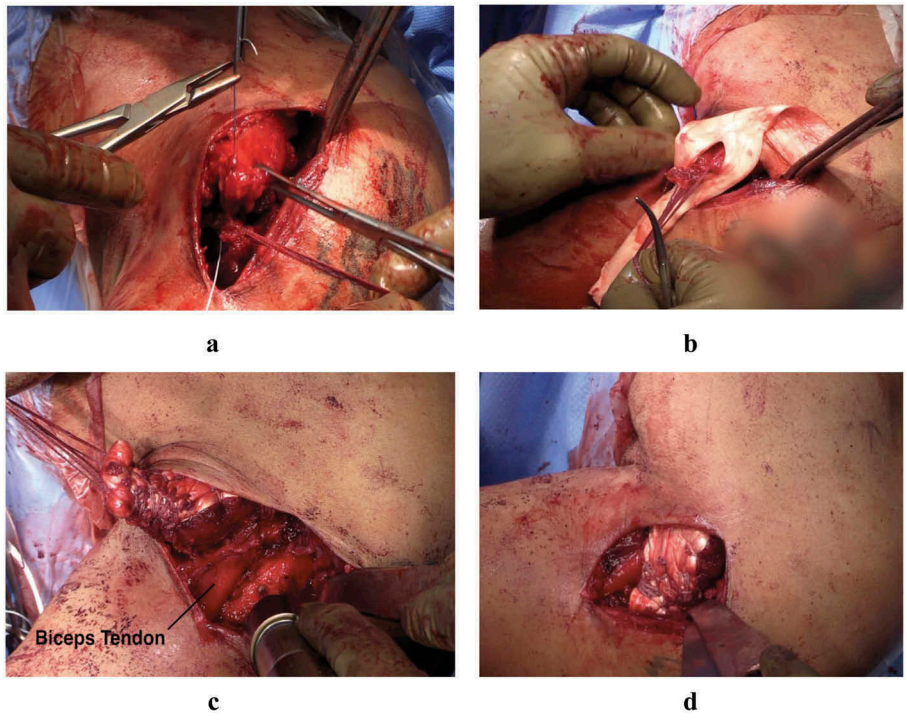

Figure 7. Chronic pectoralis major rupture (Left to Right) (a) Restoration of both tendons remnants (b) Pulvertaft weave with native tendon passed through achilles allograft (c) Insertion point created with burr lateral to biceps tendon (d) Tendon attached to the humerus.

site morbidity because of the requirement of a graft cross-section [62]. Native tissue needs to be mobilized to the humerus to create a broad footprint and larger recipient sockets in humerus are necessary, which can lead to theoretical fracture risk [62].

The effectiveness of delayed repair

Multiple case series and meta-analyses have been completed questioning the effectiveness of acute repair over delayed repair (>8 weeks) [1,2,8,17,24]. Results showed 50–100% of patients with delayed repair had excellent/good outcomes, varying between studies (Table 6). These studies indicated strength, satisfaction with outcome and satisfaction with cosmesis were slightly lower than acute repair, but still resulted in acceptable outcomes. Antosh et al. showed DASH (Disabilities of the Arm, Shoulder, and Hand) scores, and work modules score were higher in delayed repair patients (DASH = 29.17, work = 19.72) than acute repair patients (DASH = 7.81, work = 7.50) indicating more disability, but still categorized as a minimal level of disability [17]. Regardless, strength, satisfaction, and outcomes were still significantly better than nonoperative treatment.

Indications and approaches for pectoralis major transfers

Indications

Pectoralis major transfers were first utilized by Wirth and Rockwood for treatment of irreparable subscapularis injury [65]. The objectives of a tendon transfer involve the creation of line of pull similar to the deficient tendon, restoration of joint forces and full PROM, and maintaining adequate excursion [66]. Although the reverse shoulder arthroplasty has become the more favorable procedure, pectoralis major tendon transfer is an alternative [67]. Indications for a pectoralis major transfer include irreparable cuff tears, isolated incidents (e.g. atrophy), open anterior stabilization, anterior supraspinatus tears, posterior superior tears, and significant functional limitation or pain [68–71]. Contraindications to a pectoralis major transfer include irreparable posterior superior cuff tear, advanced glenohumeral osteoarthritis, deltoid dysfunction, denervation, direct injury, and recurrent glenohumeral anterior instability or subluxation [68].

The ideal patient for a pectoralis major transfer is younger than 60–65, active and has a high demand of the muscle [68]. The patient should have pain, dysfunction, and weakness of the muscle. Anatomically, the glenohumeral joint should be preserved and centered with minimal arthritis (Figure 8). The deltoid and posterior superior rotator cuff should be intact or at least reparable. The lift-off test, internal rotation lag sign, the belly-press test, the belly-off sign, and bear hug test can be utilized to test subscapularis integrity [70].

Surgical approaches

The pectoralis major tendon is advantageous for transfer as it has the second longest excursion of 18.8 cm[33]. There are various surgical approaches to a pectoralis major transfer including superficial to conjoint transfer, deep to conjoint, split, whole muscle, and sternal head transfer [72]. Rockwood and Wirth first described the pectoralis major muscle transfer using the superficial to conjoint transfer technique [72]. The release of the superior 3 cm of the tendon is released from the insertion on the greater tubercle of the humerus and sutured into the lateral edge of the bone trough [72]. Resch describes both the split and whole muscle transfer techniques [70]. The split technique transfers the superior two-thirds of the pectoralis major tendon under the conjoined tendon to mimic the subscapularis, whereas the whole muscle technique involves transferring the entire tendon [70]. Warner's technique transfers the inferior portion of the sternal head deep to the clavicular

Table 6. Chronic Surgical Outcomes (>8 weeks).

Reference	Year	Study Type	No. of Surgical Patients	Average Post-op Follow up	Surgical Outcomes	Comments
Kretzler and Richardson [24]	1989	Retrospective case series	16	Not specified	13/16 (81.3%) return to full strength	15/16 regained full range of motion
Bak et al. [2]	2000	Meta-analysis	12	Not specified	10/12 (83.3%) excellent/good	No poor outcomes, compared to 9/24 poor in conservative treatment cohort.
Schepsis et al. [8]	2000	Retrospective case series	7	28 mo. (18 mo-6 yr)	93% of the chronic group were satisfied	Strength returned to 80% – 100%, with an average of 90%. Average satisfaction with cosmesis of 84%, with a range of 70% to 95%. Peak torques between 74% and 110%
Aarimaa et al. [1][a]	2004	Meta-analysis	19	4.4 yrs (6 mo–10yr)	19/19 (100%) excellent/good	Use of anabolic steroids associated with better outcome
Antosh et al. [17][b]	2009	Retrospective case series	6	Not specified	3/6 (50%) excellent/good	83.3% reported satisfaction Higher scores in sports modules, DASH, and work module indicating more disability than the acute cohort. 4/6 returned to work before 6 months.
Nute et al. [52]	2017	Retrospective case series	257	47.8 mo (24 – 90 mo)	231/257 (90%) excellent/good	94% returned to work in average 7.1 months. 14% experienced minor complications 12% experienced major complications

[a]Chronic repair defined as >3 weeks
[b]Chronic repair defined as >6 weeks

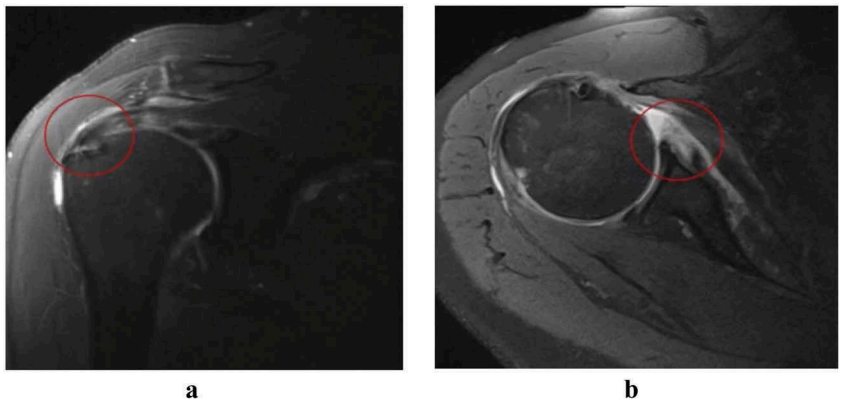

Figure 8. (a) Coronal T2 imaging shows enlargement of anterior-posterior rotator cuff tear (b) Subscapularis tendon tear with retraction to the glenoid and significant fatty atrophy.

head and superficial to the conjoined tendon into the lesser tuberosity in order to avoid the musculocutaneous nerve [71]. Klepps modified Resch's subcoracoid transfer by transferring the entire tendon deep to the conjoint tendon, superficial to musculocutaneous nerve, and attaching it the tendon to the greater tuberosity [73].

Currently, it is still controversial whether the more advantageous method is underneath or over the conjoint tendon. Placing the pectoralis major tendon superficial to the conjoint tendon provides less anterior and superior stability, but avoids nerve injury [74]. The subcoracoid transfer allows better dynamic stability along the downward and posterior vector, however placing the tendon underneath risks injury to the musculocutaneous nerve and brachial plexus [67,73]. Tendon fixation has not shown a statistically significant difference between transosseous repair, suture anchor, unicortical button or bone trough [47,75].

Operative technique

The author's preferred technique is the subcoracoid approach due to the similar line of action to pectoralis major tendon has to the subscapularis muscle (Figure 9) [67,74]. From a biomechanical standpoint, the anatomy of the coracoid base acts as a pulley, maximizes strength, increases passive muscle tension, and optimizes the direction of muscle contraction [73,74]. This technique has shown to have a low complication rate and higher patient satisfaction than the supracoracoid approach [73].

The subcoracoid pectoralis major transfer begins with the patient in the beach-chair position, under general anesthesia, with an interscalene block in the cervical plexus$_{49}$. The patient's limb should be placed in the pneumatic arm hold and an anterior dissection is made for a deltopectoral approach [70]. The pectoralis major muscle insertion is exposed, sternocostal head identified and sharply detached as close to the humeral shaft as possible (lateral to intertubercular groove) [70]. The biceps

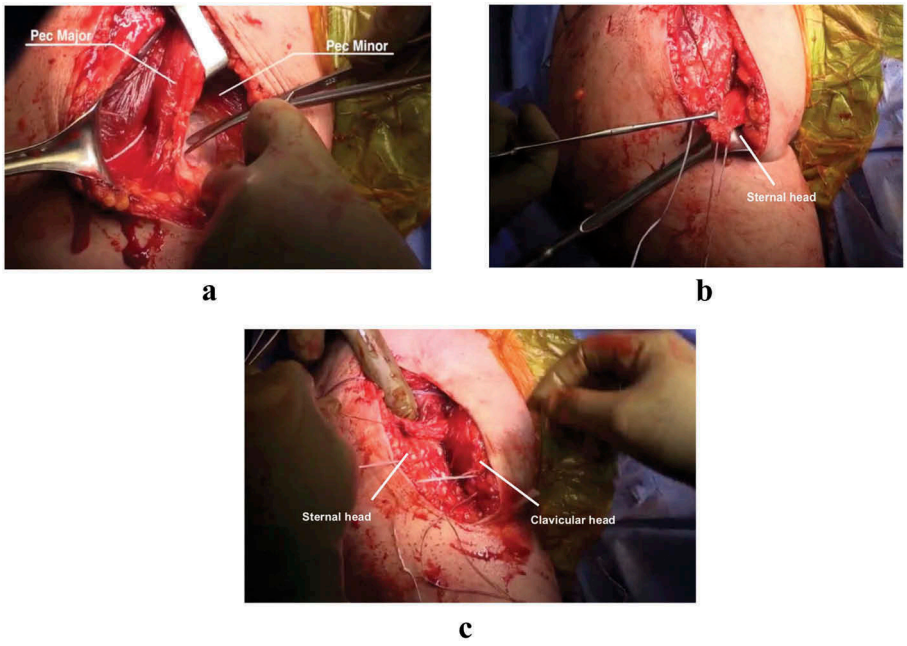

Figure 9. Pectoralis major tendon transfer (a) Isolation of tendon insertion to view the clavicular and sternal heads (b) Sternal head removed from the humeral side with locking sutures inserted (c) Sternal head passed underneath the clavicular head.

tendon and axillary nerve must be protected, as well as the musculocutaneous nerve located 5–6 cm from the coracoid tip with the proximal branch 2–4 cm from coracoid [76]. Different sutures are placed on the tendon to maintain orientation after transfer [73]. The muscle is advanced behind the conjoint tendon, superficial to musculocutaneous nerve and attached to the lesser tuberosity or greater tuberosity with bone tunnels or suture anchors [73]. Following the transfer, palpation of the musculocutaneous nerve is performed to ensure the nerve has no extra tension [73]. If excessive tension is placed, the proximal nerve is released followed by tendon debulking [20].

Postoperative rehabilitation

Postoperative rehabilitation begins with immobilization with an abduction pillow and active elbow, wrist, and hand motion for the first 4–6 weeks [68]. Passive ROM, including forward flexion and external rotation, begins between 6 and 12 weeks based on intra-operative assessment [65,70,71,77]. Strength training has been recommended as early 6 weeks after surgery or after regaining full passive range of motion, while other physicians suggest waiting until after week 12 [65,70,71,77].

Outcomes of pectoralis major tendon transfer

Patients with pectoralis major tendon transfer for subscapularis tears have shown significant improvement [65,70,78,79]. Numerous studies have shown an increase in shoulder patient-reported scores, improvement in range of motion, strength, and exercise tolerance across all ages [65,70,78,79]. The most common complications are activity-related-pain, decreased external rotation due to the tenodesis effect of the transferred pectoralis major tendon, and recurrent instability [67]. Larger rotator cuff tears creating insufficiency resulted in lower patient-reported scores mostly due to the addition of rotator cuff disease [67,78,79]. However, these patients still demonstrated improvement in range of motion and function [67,78,79]. In general, the patient reported outcomes are satisfactory, although the level of functional gains is unpredictable [67,80].

Conclusion

Pectoralis major ruptures are uncommon and occur most frequently in young males in the athlete and military populations. Such tears are diagnosed with an MRI of the chest wall with axial slices from the quadrilateral space to deltoid tuberosity. Nonoperative treatment is indicated for patients with incomplete tears, irreparable damage or who are unable or unwilling due to medical comorbidities or age. Patients with nonoperative treatment often experience a significant decrease in strength and lower satisfaction with cosmesis, yet report good or excellent outcomes. All studies where acute surgery was defined less than 6 weeks showed 90% of patients or greater had excellent or good outcomes, thus demonstrating repair before 6 weeks is the most effective. Patients with delayed repair post injury showed a lower percentage of excellent or good outcomes. Regardless, strength, satisfaction, and outcomes were still significantly better than nonoperative treatment. Reconstruction is reserved for a complete disruption of the entire insertion site, significant muscle belly or tendon retraction, or distorted tissue quality. Graft options for reconstruction include hamstring autograft, achilles allograft, dermal allograft patch, and fascia lata allograft. Pectoralis major tendon transfers, utilized for patients with subscapularis failure, atrophy, rotator cuff tears, or significant functional limitation or pain have been shown to have unpredictable outcomes, but overall satisfactory results.

Description

After a comprehensive review of literature in addition to collecting the leading experts opinions, we present an analysis of pectoralis major ruptures. This review article includes anatomy and biomechanics of the pectoralis major muscle, proper evaluation of the patient, operative and nonoperative treatment of acute and chronic pectoralis major ruptures, and outcomes of the recommended treatments. All authors were involved with the writing and revising the manuscript.

Funding

This manuscript was funded by NYU Langone Health, Orthopaedic Surgery, Division of Sports Medicine.

Declaration of interest

M Alaia declares paid speakers fees and research support from Arthrex, Inc., and is also a Board/Committee member of the Arthroscopy Association of North America. M Zacchilli is also a Board/Committee member of the Arthroscopy Association of North America, and also sits on the governing board for the *Journals of Special Operations Medicine*. Y Kwon is a paid consultant for DJ Orthopaedics. E Flatow is a Board/Committee member of AAOS and the Health Association of NY. They also declare IP royalties from Innomed and Zimmer, and publishing royalties from Sprinter. E Flatow sits on the Editorial board for *Journal of Shoulder and Elbow Surgery*. L Jazrawi has received research support from Arthrex and Mitek. They have also received publishing royalties, financial or material support from Wolters Kluwer Health-Lippincott Williams & Wilkins. E Strauss declares paid consultancy/speakers fees from Arthrex Inc., sitting on the Editorial board for *Cartilage* and *Bulletin of the Hospital for Joint Diseases*, research support from Fidia, and paid consultancy for Flexion Therapeutics, Joint Restoration Foundation, Mitek and Vericel. E Strauss also declares research support from NuTech and publishing royalties from Jaypoo Publishing.

References

1. Aarimaa V, Rantanen J, Heikkila J, et al. Rupture of the pectoralis major muscle. Am J Sports Med. 2004;32(5):1256–1262.
2. Bak K, Cameron EA, Henderson IJ. Rupture of the pectoralis major: a meta-analysis of 112 cases. Knee Surg Sports Traumatol Arthrosc. 2000;8(2):113–119.
3. de Castro Pochini A, Ejnisman B, Andreoli CV, et al. Pectoralis major muscle rupture in athletes: a prospective study. Am J Sports Med. 2010;38(1):92–98.
4. ElMaraghy AW, Devereaux MW. A systematic review and comprehensive classification of pectoralis major tears. J Shoulder Elbow Surg. 2012;21(3):412–422.
5. Hanna CM, Glenny AB, Stanley SN, et al. Pectoralis major tears: comparison of surgical and conservative treatment. Br J Sports Med. 2001;35(3):202–206.
6. Joseph TA, Defranco MJ, Weiker GG. Delayed repair of a pectoralis major tendon rupture with allograft: a case report. J Shoulder Elbow Surg. 2003;12(1):101–104.
7. Lee J, Brookenthal KR, Ramsey ML, et al. MR imaging assessment of the pectoralis major myotendinous unit: an MR imaging-anatomic

correlative study with surgical correlation. AJR Am J Roentgenol. 2000;174(5):1371–1375.
8. Schepsis AA, Grafe MW, Jones HP, et al. Rupture of the pectoralis major muscle. Outcome after repair of acute and chronic injuries. Am J Sports Med. 2000;28(1):9–15.
9. Chiavaras MM, Jacobson JA, Smith J, et al. Pectoralis major tears: anatomy, classification, and diagnosis with ultrasound and MR imaging. Skeletal Radiol. 2015;44(2):157–164.
10. Dodds SD, Wolfe SW. Injuries to the pectoralis major. Sports Med. 2002;32(14):945–952.
11. Petilon J, Carr DR, Sekiya JK, et al. Pectoralis major muscle injuries: evaluation and management. J Am Acad Orthop Surg. 2005;13 (1):59–68.
12. Provencher MT, Handfield K, Boniquit NT, et al. Injuries to the pectoralis major muscle: diagnosis and management. Am J Sports Med. 2010;38(8):1693–1705.
13. Tietjen R. Closed injuries of the pectoralis major muscle. J Trauma. 1980;20(3):262–264.
14. He ZM, Ao YF, Wang JQ, et al. Twelve cases of the pectoralis major muscle tendon rupture with surgical treatment-an average of 6.7-year follow-up. Chin Med J (Engl). 2010;123(1):57–60.
15. Pavlik A, Csepai D, Berkes I. Surgical treatment of pectoralis major rupture in athletes. Knee Surg Sports Traumatol Arthrosc. 1998;6 (2):129–133.
16. Roi GS, Respizzi S, Dworzak F. Partial rupture of the pectoralis major muscle in athletes. Int J Sports Med. 1990;11(1):85–87.
17. Antosh IJ, Grassbaugh JA, Parada SA, et al. Pectoralis major tendon repairs in the active-duty population. Am J Orthop (Belle Mead NJ). 2009;38(1):26–30.
18. Cordasco FA, Mahony GT, Tsouris N, et al. Pectoralis major tendon tears: functional outcomes and return to sport in a consecutive series of 40 athletes. J Shoulder Elbow Surg. 2017;26(3):458–463.
19. Wolfe SW, Wickiewicz TL, Cavanaugh JT. Ruptures of the pectoralis major muscle. An anatomic and clinical analysis. Am J Sports Med. 1992;20(5):587–593.
20. Klepps SJ, Goldfarb C, Flatow E, et al. Anatomic evaluation of the subcoracoid pectoralis major transfer in human cadavers. J Shoulder Elbow Surg. 2001;10(5):453–459.
21. Schachter AK, White BJ, Namkoong S, et al. Revision reconstruction of a pectoralis major tendon rupture using hamstring autograft: a case report. Am J Sports Med. 2006;34(2):295–298.
22. Sikka RS, Neault M, Guanche CA. Reconstruction of the pectoralis major tendon with fascia lata allograft. Orthopedics. 2005;28 (10):1199–1201.
23. Zafra M, Munoz F, Carpintero P. Chronic rupture of the pectoralis major muscle: report of two cases. Acta Orthop Belg. 2005;71 (1):107–110.
24. Kretzler HH Jr., Richardson AB. Rupture of the pectoralis major muscle. Am J Sports Med. 1989;17(4):453–458.
25. Porzionato A, Macchi V, Stecco C, et al. Surgical anatomy of the pectoral nerves and the pectoral musculature. Clin Anat. 2012;25 (5):559–575.
26. P K, S K. Anatomical study of pectoral nerves and its implications in surgery. J Clin Diagn Res. 2014;8(7):AC01–05.
27. Fung L, Wong B, Ravichandiran K, et al. Three-dimensional study of pectoralis major muscle and tendon architecture. Clin Anat. 2009;22(4):500–508.
28. Balazs GC, Brelin AM, Donohue MA, et al. Incidence rate and results of the surgical treatment of pectoralis major tendon ruptures in active-duty military personnel. Am J Sports Med. 2016;44(7):1837–1843.
29. Kakwani RG, Matthews JJ, Kumar KM, et al. Rupture of the pectoralis major muscle: surgical treatment in athletes. Int Orthop. 2007;31(2):159–163.
30. Giangarra CE, Manske RC. Clinical orthopaedic rehabilitation: a team approach. Vol. 4. Elsevier; 2018.
31. Al-Ahaideb A. Pectoralis major rupture in athletes. Saudi J Sports Med. 2014;14:1.
32. Butt U, Mehta S, Funk L, et al. Pectoralis major ruptures: a review of current management. J Shoulder Elbow Surg. 2015;24(4):655–662.
33. Edgar CM, Singh H, Obopilwe E, et al. Pectoralis major repair: a biomechanical analysis of modern repair configurations versus traditional repair configuration. Am J Sports Med. 2017;45 (12):2858–2863.
34. Samitier GS, Marcano AI, Farmer KW. Pectoralis major transosseous equivalent repair with knotless anchors: technical note and literature review. Int J Shoulder Surg. 2015;9(1):20–23.
35. ElMaraghy AW, Rehsia SS, Pennings AL. Utility of the pectoralis major index in the diagnosis of structurally significant pectoralis major tears. Orthop J Sports Med. 2013;1(7):2325967113516729.
36. Ohashi K, El-Khoury GY, Albright JP, et al. MRI of complete rupture of the pectoralis major muscle. Skeletal Radiol. 1996;25(7):625–628.
37. Shepard NP, Westrick RB, Owens BD, et al. Bony avulsion injury of the pectoralis major in a 19 year-old male judo athlete: a case report. Int J Sports Phys Ther. 2013;8(6):862–870.
38. Kircher J, Ziskoven C, Patzer T, et al. Surgical and nonsurgical treatment of total rupture of the pectoralis major muscle in athletes: update and critical appraisal. Open Access J Sports Med. 2010;1:201–205.
39. Manske RC, Prohaska D. Pectoralis major tendon repair post surgical rehabilitation. N Am J Sports Phys Ther. 2007;2(1):22–33.
40. Fleury AM, Silva AC, de Castro Pochini A, et al. Isokinetic muscle assessment after treatment of pectoralis major muscle rupture using surgical or non-surgical procedures. Clinics (Sao Paulo). 2011;66(2):313–320.
41. de Castro Pochini A, Andreoli CV, Belangero PS, et al. Clinical considerations for the surgical treatment of pectoralis major muscle ruptures based on 60 cases: a prospective study and literature review. Am J Sports Med. 2014;42(1):95–102.
42. Haley CA, Zacchilli MA. Pectoralis major injuries: evaluation and treatment. Clin Sports Med. 2014;33(4):739–756.
43. Merolla G, Paladini P, Campi F, et al. Pectoralis major tendon rupture. Surgical procedures review. Muscles Ligaments Tendons J. 2012;2(2):96–103.
44. Wurm M, Imhoff AB, Siebenlist S. Surgical repair of acute pectoralis major muscle ruptures. Oper Orthop Traumatol. 2018;30 (6):390–397.
45. Metzger PD, Bailey JR, Filler RD, et al. Pectoralis major muscle rupture repair: technique using unicortical buttons. Arthrosc Tech. 2012;1(1):e119–125.
46. Gautschi OP, Zellweger R. A complete tear of the pectoralis major muscle from a seat belt injury. Eur J Emerg Med. 2007;14(2):90–91.
47. Merolla G, Paladini P, Artiaco S, et al. Surgical repair of acute and chronic pectoralis major tendon rupture: clinical and ultrasound outcomes at a mean follow-up of 5 years. Eur J Orthop Surg Traumatol. 2015;25(1):91–98.
48. Schmidt A, Johann K. [Ruptures of the pectoralis major muscle - clinical results after operative and non-operative treatment]. Sportverletz Sportschaden. 2007;21(4):185–189.
49. Silverstein JA, Goldberg B, Wolin P. Proximal humerus shaft fracture after pectoralis major tendon rupture repair. Orthopedics. 2011;34 (6):222.
50. Guity M, Sharafat Vaziri A, Shafiei H, et al. Surgical treatment of pectoralis major tendon rupture (outcome assessment). Asian J Sports Med. 2014;5(2):129–135.
51. Kang RW, Mahony GT, Cordasco FA. Pectoralis major repair with cortical button technique. Arthrosc Tech. 2014;3(1):e73–77.
52. Nute DW, Kusnezov N, Dunn JC, et al. Return to function, complication, and reoperation rates following primary pectoralis major tendon repair in military service members. J Bone Joint Surg Am. 2017;99(1):25–32.
53. Orava S, Sorasto A, Aalto K, et al. Total rupture of pectoralis major muscle in athletes. Int J Sports Med. 1984;5(5):272–274.
54. Zvijac JE, Schurhoff MR, Hechtman KS, et al. Pectoralis major tears: correlation of magnetic resonance imaging and treatment strategies. Am J Sports Med. 2006;34(2):289–294.
55. Yu J, Zhang C, Horner N, et al. Outcomes and return to sport after pectoralis major tendon repair: a systematic review. Sports Health. 2019;11(2):134–141.

56. Alho A. Ruptured pectoralis major tendon. A case report on delayed repair with muscle advancement. Acta Orthop Scand. 1994;65(6):652–653.
57. McEntire JE, Hess WE, Coleman SS. Rupture of the pectoralis major muscle. A report of eleven injuries and review of fifty-six. J Bone Joint Surg Am. 1972;54(5):1040–1046.
58. Inhofe PD, Grana WA, Egle D, et al. The effects of anabolic steroids on rat tendon. An ultrastructural, biomechanical, and biochemical analysis. Am J Sports Med. 1995;23(2):227–232.
59. Tsitsilonis S, Chatzistergos PE, Mitousoudis AS, et al. Anabolic androgenic steroids reverse the beneficial effect of exercise on tendon biomechanics: an experimental study. Foot Ankle Surg. 2014;20(2):94–99.
60. Dehler T, Pennings AL, ElMaraghy AW. Dermal allograft reconstruction of a chronic pectoralis major tear. J Shoulder Elbow Surg. 2013;22(10):e18–22.
61. Flint JH, Wade AM, Giuliani J, et al. Defining the terms acute and chronic in orthopaedic sports injuries: a systematic review. Am J Sports Med. 2014;42(1):235–241.
62. Baverel L, Messedi K, Pietu G, et al. Pectoralis major tear with retracted tendon: how to fill the gap? Reconstruction with hamstring autograft and fixation with an interference screw. Case Rep Orthop. 2017;2017:2095407.
63. Barbour SA, King W. The safe and effective use of allograft tissue–an update. Am J Sports Med. 2003;31(5):791–797.
64. Zacchilli MA, Fowler JT, Owens BD. Allograft reconstruction of chronic pectoralis major tendon ruptures. J Surg Orthop Adv. 2013;22(1):95–102.
65. Wirth MA, Rockwood CA Jr. Operative treatment of irreparable rupture of the subscapularis. J Bone Joint Surg Am. 1997;79(5):722–731.
66. Shin JJ, Saccomanno MF, Cole BJ, et al. Pectoralis major transfer for treatment of irreparable subscapularis tear: a systematic review. Knee Surg Sports Traumatol Arthrosc. 2016;24(6):1951–1960.
67. Nelson GN, Namdari S, Galatz L, et al. Pectoralis major tendon transfer for irreparable subscapularis tears. J Shoulder Elbow Surg. 2014;23(6):909–918.
68. Boatright JD, Crow AJ, Brockmeier SF. Pectoralis major tendon transfer. (*Massive Rotator Cuff Tears*). 2014:101–120.
69. Mendes GdC, Petrucci, C.V, Monteiro R.L, et al. Functional results after transfer of the pectoralis major muscle in subscapularis tears: a literature review. Int J Orthop. 2014;1(2):43–46.
70. Resch H, Povacz P, Ritter E, et al. Transfer of the pectoralis major muscle for the treatment of irreparable rupture of the subscapularis tendon. J Bone Joint Surg Am. 2000;82(3):372–382.
71. Warner JJ. Management of massive irreparable rotator cuff tears: the role of tendon transfer. Instr Course Lect. 2001;50:63–71.
72. Herzberg G, Urien JP, Dimnet J. Potential excursion and relative tension of muscles in the shoulder girdle: relevance to tendon transfers. J Shoulder Elbow Surg. 1999;8(5):430–437.
73. Klepps S, Galatz, L, Yamaguchi, K, et al. Subcoracoid pectoralis major transfer: a salvage procedure for irreparable subscapularis deficiency. Tech Shoulder Elbow Surg. 2001;2(2):85–91.
74. Konrad GG, Sudkamp NP, Kreuz PC, et al. Pectoralis major tendon transfers above or underneath the conjoint tendon in subscapularis-deficient shoulders. An in vitro biomechanical analysis. J Bone Joint Surg Am. 2007;89(11):2477–2484.
75. Hart ND, Lindsey DP, McAdams TR. Pectoralis major tendon rupture: a biomechanical analysis of repair techniques. J Orthop Res. 2011;29(11):1783–1787.
76. Flatow EL, Bigliani LU, April EW. An anatomic study of the musculocutaneous nerve and its relationship to the coracoid process. Clin Orthop Relat Res. 1989 Jul;(244):166–171.
77. Galatz LM, Connor PM, Calfee RP, et al. Pectoralis major transfer for anterior-superior subluxation in massive rotator cuff insufficiency. J Shoulder Elbow Surg. 2003;12(1):1–5.
78. Elhassan B, Ozbaydar M, Massimini D, et al. Transfer of pectoralis major for the treatment of irreparable tears of subscapularis: does it work? J Bone Joint Surg Br. 2008;90(8):1059–1065.
79. Jost B, Puskas GJ, Lustenberger A, et al. Outcome of pectoralis major transfer for the treatment of irreparable subscapularis tears. J Bone Joint Surg Am. 2003;85-A(10):1944–1951.
80. Omid R, Lee B. Tendon transfers for irreparable rotator cuff tears. J Am Acad Orthop Surg. 2013;21(8):492–501.